



Seminar "Research developments in horse breeding for improved health",
19th September 2013, Uppsala / Sweden

Standardized recording of equine health data in Germany

S. Sarnowski, K.F. Stock

Vereinigte Informationssysteme Tierhaltung w. V. (vit), Verden, Germany
& Institute for Animal Breeding and Genetics,
University of Veterinary Medicine Hannover (Foundation), Hannover, Germany

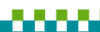

H. WILHELM SCHAUMANN STIFTUNG

Background

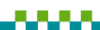

- increasing interest of equine industry in health & longevity
→ relevance as breeding goal trait ↑
- breeding measures to improve health in German riding horses
 - mainly indirect selection (indicator traits: conformation, performance)
 - some direct selection (extreme phenotypes / stallions)
- legal framework
 - animal breeding act (national)
 - breeding organization directive of the German FN (national)
 - regulations of the breeding societies (N=16 for riding horses)



Recent developments

- inclusion of defects traits and indications of disease in linear profiling protocols (Oldenburg, Holstein; since 2011)
- harmonization initiative of breeding societies & veterinarians: health requirements for stallion approval
 - working group 2012-2013
 - agreement on uniform criteria to be applied as of 2013
- joint project with more general approach: **improved information basis on equine health**
 - partners: Warmblood breeding societies & veterinarians, German FN, vit, universities
 - aim: extension of breeding databases by information on equine health (central availability for routine analyses)

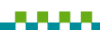

Health data recording (status quo)

- routine documentation of veterinarians
 - veterinary software
 - examination protocols e.g. for candidate sires
- at most rudimentary tools for simplified documentation
 - some tick boxes / selection lists
 - mostly free text
 → lack of tools for standardized documentation of health data
- no systematic collection of health data by breeding organizations



key action 1:
development of recording standards for diagnoses & findings



Recording standards

- requirements
 - clear distinction between diagnoses (diseases) and findings of disease
 - unambiguous definitions of all health items to be recorded: diagnoses, radiographic findings, clinical findings, ...
 - unambiguous coding
 - praxis-oriented spectrum of recording options
- realization
 - distinct recording standards for diagnoses, radiographic findings, ...
 - hierarchical structure
 - comprehensive lists (all organ systems, inherited & acquired conditions, descriptive & etiologic aspects)



Key of diagnoses (EQUINE)

| Diagnosis code | Diagnosis |
|----------------|---|
| 1. | Organ diseases |
| 1.01. | Diseases of skin, subcutis and coat |
| 1.02. | Diseases of trunk and visceral cavities |
| 1.03. | Cardio-vascular diseases |
| 1.04. | Diseases of blood and blood forming organs |
| 1.05. | Respiratory diseases |
| 1.06. | Diseases of head |
| 1.07. | Diseases of oral cavity, tongue, hyoid bone and teeth |
| 1.08. | Gastrointestinal diseases |
| 1.09. | Diseases of liver |
| 1.10. | Metabolic diseases and tumorous disorders of hormone forming organs |
| 1.11. | Diseases of the urinary tract |
| 1.12. | Reproductive disorders |
| 1.13. | Disease of nervous system and eyes |
| 1.14. | Musculoskeletal diseases |
| 2. | Infectious diseases |
| 3. | Parasitoses |
| 4. | Behavioral disorders |

- Structure:
- 4 disease groups
 - levels of increasing detailedness (max. 7)
 - in total > 2000 recording options



Key of findings (EQUINE)

- distinct sections for
 - radiographic findings
 - clinical findings incl. outcomes of specific examinations (ophthalmological, cardiological, ...)
- general outline
 - clear base structure relating to examination conditions
 - unambiguous, purely descriptive, common terminology

Radiographic findings section

- documentation by projection
- categories of findings independent of projection and location:
 - structure changes (radiolucency, increased radiodensity),
 - contour changes (exostoses, indentions),
 - further changes (specific findings like canales sesamoidales, osseous fragments, ...)



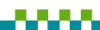Standardized recording

- general acceptance of recording standards as base requirement
 - model: 'central key for health data recording' (CATTLE)
 - science-driven development with consultation of experts (spectrum of diagnoses / findings, terminology)
- use of recording standards dependent on
 - ease of documentation (time, clearness)
 - flexibility regarding amount & detailedness of documentation
 - broad spectrum of documentation options (minimization of free text)
 - compatibility with documentation routines in the veterinary practice



key action 2:

practically feasible implementation of standardized recording
→ veterinary software

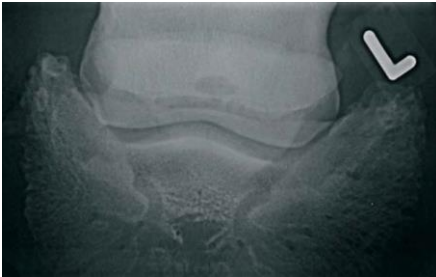


Key of radiographic findings (EXAMPLE)

Rad. examination of the front limbs

| | | | |
|---|---------------------------------------|---|--|
| <input checked="" type="checkbox"/> vorne links | <input type="checkbox"/> vorne rechts | <input type="checkbox"/> hinten links | <input type="checkbox"/> hinten rechts |
| <input checked="" type="checkbox"/> RÖUS Zehe distal (<input checked="" type="checkbox"/> Oxspring <input type="checkbox"/> 90°) | | <input type="checkbox"/> Zusatzaufnahmen Zehe distal (<input type="checkbox"/> Skyline <input type="checkbox"/> 0° <input type="checkbox"/> 45° / <input type="checkbox"/> 315°) | |

Figure: cyst-like lesion in the front left sesamoid bone



*circumscribed radiolucency in front left front limb visible on upright-pedal-view (Oxspring projection)
→ diagnosis: cyst-like lesion*

Key of radiographic findings (EXAMPLE)

Rad. examination of the front limbs

| | | | |
|---|---------------------------------------|---|--|
| <input checked="" type="checkbox"/> vorne links | <input type="checkbox"/> vorne rechts | <input type="checkbox"/> hinten links | <input type="checkbox"/> hinten rechts |
| <input checked="" type="checkbox"/> RÖUS Zehe distal (<input checked="" type="checkbox"/> Oxspring <input type="checkbox"/> 90°) | | <input type="checkbox"/> Zusatzaufnahmen Zehe distal (<input type="checkbox"/> Skyline <input type="checkbox"/> 0° <input type="checkbox"/> 45° / <input type="checkbox"/> 315°) | |

| Befundschlüssel (Code) - R1 | Befund |
|-----------------------------|---|
| 1.00. | <input checked="" type="checkbox"/> Strahlbein röntgenologisch o.b.B. |
| 2.00. | <input checked="" type="checkbox"/> Hufbein und angrenzende Strukturen röntgenologisch o.b.B. |
| 3.00. | <input checked="" type="checkbox"/> Kronbein röntgenologisch o.b.B. |

*circumscribed radiolucency in front left front limb visible on upright-pedal-view (Oxspring projection)
→ diagnosis: cyst-like lesion*

Key of radiographic findings (EXAMPLE)

Rad. examination of the front limbs

| <input checked="" type="checkbox"/> vorne links <input type="checkbox"/> vorne rechts <input type="checkbox"/> hinten links <input type="checkbox"/> hinten rechts | |
|---|---|
| <input checked="" type="checkbox"/> RÖUS Zehe distal (<input checked="" type="checkbox"/> Oxspring <input type="checkbox"/> 90°) <input type="checkbox"/> Zusatzaufnahmen Zehe distal (<input type="checkbox"/> Skyline <input type="checkbox"/> 0° <input type="checkbox"/> 45° / <input type="checkbox"/> 315°) | |
| Befundschlüssel (Code) - R1 | Befund |
| 1.00. | <input checked="" type="checkbox"/> Strahlbein röntgenologisch o.b.B. |
| 2.00. | <input checked="" type="checkbox"/> Hufbein und angrenzende Strukturen röntgenologisch o.b.B. |
| 3.00. | <input type="checkbox"/> Kronbein röntgenologisch o.b.B. |
| 3.01. | <input type="checkbox"/> Strukturveränderung des Kronbeins |
| 3.02. | <input type="checkbox"/> Konturveränderung des Kronbeins |
| 3.03. | <input type="checkbox"/> weitere röntg. Befunde an Kronbein und Krongelenk |

circumscribed radiolucency in front left front limb visible on upright-pedal-view (Oxspring projection) → diagnosis: cyst-like lesion



Key of radiographic findings (EXAMPLE)

Rad. examination of the front limbs

| <input checked="" type="checkbox"/> vorne links <input type="checkbox"/> vorne rechts <input type="checkbox"/> hinten links <input type="checkbox"/> hinten rechts | |
|---|---|
| <input checked="" type="checkbox"/> RÖUS Zehe distal (<input checked="" type="checkbox"/> Oxspring <input type="checkbox"/> 90°) <input type="checkbox"/> Zusatzaufnahmen Zehe distal (<input type="checkbox"/> Skyline <input type="checkbox"/> 0° <input type="checkbox"/> 45° / <input type="checkbox"/> 315°) | |
| Befundschlüssel (Code) - R1 | Befund |
| 1.00. | <input checked="" type="checkbox"/> Strahlbein röntgenologisch o.b.B. |
| 2.00. | <input checked="" type="checkbox"/> Hufbein und angrenzende Strukturen röntgenologisch o.b.B. |
| 3.00. | <input type="checkbox"/> Kronbein röntgenologisch o.b.B. |
| 3.01. | <input checked="" type="checkbox"/> Strukturveränderung des Kronbeins |
| 3.01.01. | <input type="checkbox"/> extraartikuläre Aufhellung des Kronbeins |
| 3.01.02. | <input type="checkbox"/> Aufhellung im distalen Kronbein |
| 3.01.03. | <input type="checkbox"/> Aufhellung im proximalen Kronbein |
| 3.02.01. | <input type="checkbox"/> extraartikuläre Verschattung des Kronbeins |
| 3.02.02. | <input type="checkbox"/> Verschattung im distalen Kronbein |
| 3.02.03. | <input type="checkbox"/> Verschattung im proximalen Kronbein |
| 3.02. | <input type="checkbox"/> Konturveränderung des Kronbeins |
| 3.03. | <input type="checkbox"/> weitere röntg. Befunde an Kronbein und Krongelenk |

circumscribed radiolucency in front left front limb visible on upright-pedal-view (Oxspring projection) → diagnosis: cyst-like lesion



Key of radiographic findings (EXAMPLE)



Rad. examination of the front limbs

vorne links vorne rechts hinten links hinten rechts

RÖUS Zehe distal (Oxspring 90°) Zusatzaufnahmen Zehe distal (Skyline 0° 45° / 315°)

| Befundschlüssel (Code) - R1 | Befund | Zusatzinformation (Details) |
|-----------------------------|---|---|
| 1.00. | <input checked="" type="checkbox"/> Strahlbein röntgenologisch o.b.B. | |
| 2.00. | <input checked="" type="checkbox"/> Hufbein und angrenzende Strukturen röntgenologisch o.b.B. | |
| 3.00. | <input type="checkbox"/> Kronbein röntgenologisch o.b.B. | |
| 3.01. | <input checked="" type="checkbox"/> Strukturveränderung des Kronbeins | |
| 3.01.01. | <input type="checkbox"/> extraartikuläre Aufhellung des Kronbeins | |
| 3.01.02. | <input type="checkbox"/> Aufhellung im distalen Kronbein | |
| 3.01.03. | <input checked="" type="checkbox"/> Aufhellung im proximalen Kronbein | <input type="checkbox"/> diffus <input checked="" type="checkbox"/> umschrieben <input type="checkbox"/> lateral <input type="checkbox"/> axial <input checked="" type="checkbox"/> medial <input type="checkbox"/> ggr. <input type="checkbox"/> mgr. <input checked="" type="checkbox"/> hgr. |
| 3.02.01. | <input type="checkbox"/> extraartikuläre Verschattung des Kronbeins | |
| 3.02.02. | <input type="checkbox"/> Verschattung im distalen Kronbein | |
| 3.02.03. | <input type="checkbox"/> Verschattung im proximalen Kronbein | |
| 3.02. | <input type="checkbox"/> Konturveränderung des Kronbeins | |
| 3.03. | <input type="checkbox"/> weitere röntg. Befunde an Kronbein und Krongelenk | |

circumscribed radiolucency in front left front limb visible on upright-pedal-view (Oxspring projection) → diagnosis: cyst-like lesion

Key of radiographic findings (EXAMPLE)



Rad. examination of the front limbs

vorne links vorne rechts hinten links hinten rechts

RÖUS Zehe distal (Oxspring 90°) Zusatzaufnahmen Zehe distal (Skyline 0° 45° / 315°)

| Befundschlüssel (Code) - R1 | Befund | Zusatzinformation (Details) |
|-----------------------------|---|---|
| 1.00. | <input checked="" type="checkbox"/> Strahlbein röntgenologisch o.b.B. | |
| 2.00. | <input checked="" type="checkbox"/> Hufbein und angrenzende Strukturen röntgenologisch o.b.B. | |
| 3.00. | <input type="checkbox"/> Kronbein röntgenologisch o.b.B. | |
| 3.01. | <input checked="" type="checkbox"/> Strukturveränderung des Kronbeins | |
| 3.01.01. | <input type="checkbox"/> extraartikuläre Aufhellung des Kronbeins | |
| 3.01.02. | <input type="checkbox"/> Aufhellung im distalen Kronbein | |
| 3.01.03. | <input checked="" type="checkbox"/> Aufhellung im proximalen Kronbein | <input type="checkbox"/> diffus <input checked="" type="checkbox"/> umschrieben <input type="checkbox"/> lateral <input type="checkbox"/> axial <input checked="" type="checkbox"/> medial <input type="checkbox"/> ggr. <input type="checkbox"/> mgr. <input checked="" type="checkbox"/> hgr. |
| | Krongelenk | |

Standardized documentation with 3-6 clicks:
Left front limb (Oxspring)
radiolucency in the proximal short pastern bone, further characterized as circumscribed, medially located, severe/marked

circumscribed radiolucency in front left front limb visible on upright-pedal-view (Oxspring projection) → diagnosis: cyst-like lesion

Conclusions & prospects

- trustful & constructive collaboration of project partners (key action 1)
 - veterinarians of breeding societies as important drivers
 - veterinarians & animal geneticists in vit as mediators between veterinary practitioners, science and breeding
 - mutual benefits of standardized health data recording (veterinary practice, breeding)
- base work for future health data collection & analyses
 - conditions of routine use of equine health data (data security issues, regulations of breeding societies)
 - screening of historical data to increase scientific knowledge
 - fruitful talks with market leader for veterinary software in Germany: project support & soon prototype availability (key action 2)



Thank you!

Contact persons in vit (genetic evaluation division):

Sonja Sarnowski

Email: sonja.sarnowski@vit.de

Phone: +49 - 4231 - 955185

PD Dr. habil. Kathrin F. Stock

Email: friederike.katharina.stock@vit.de

Phone: +49 - 4231 - 955623 oder +49 - 176 - 60931357

Defect traits & indications of disease

- Oldenburg (OL, OS)
 - umbilical hernia
 - clinical limb status (joint swelling, swelling of tendon sheaths, epiphysitis), lameness
 - indications of imbalance (incoordination, tail tone, tail posture)
 - breathing sounds
- Holstein
 - umbilical hernia, scrotal hernia
 - overbite, underbite
 - lameness
 - indications of imbalance (incoordination, tail tone, tail posture)
 - breathing sounds



Recording standards (CATTLE)

- national
 - since June 2008: "Zentraler Diagnoseschlüssel Rind"
Appendix 1 of the recommendation 3.1.1 of the German Cattle Breeders' Federation (ADR) for recording and use of health data in cattle;
expert elaboration: Staufenbiel (FU Berlin) & coworkers;
use as recording standard in herd management software
 - since 2012: "Zentraler Tiergesundheitschlüssel Rind"
Working group for health data of the umbrella organization of German milk recording agencies (DLQ); support / updates: Staufenbiel (FU Berlin), Stock (vit)
- international
 - since 2012: "Central Key for Health Data Recording"
Appendix of the Guidelines for recording, evaluation and genetic improvement of health traits, compiled by the Functional Traits Working Group of the International Committee for Animal Recording (ICAR);
english version of the German standard (Zentralen Tiergesundheitschlüssels) as reference;
support / updates: Stock (vit)

